



ISSN: 2091-2749 (Print)
2091-2757 (Online)

Correspondence

Dr. Uttam Laudari
Department of Surgery
Patan Academy of Health
Sciences, Lalitpur, Nepal
GPO Box 26500
Email: youttam@hotmail.com

Peer Reviewers

Asst. Prof. Dr. Tripti Shakya
Patan Academy of Health
Sciences

Asst. Prof. Dr. Ashis Shrestha
Patan Academy of Health
Sciences

Submitted

4 Mar 2019

Accepted

5 Aug 2019

How to cite this article

Uttam Laudari, Shreya Bhandari, Rupesh Ramtel, Bibhuti Adhikari, Mohan Dev Bhandari. Multiloculated thymic cyst: unusual presentation of mediastinal mass. Journal of Patan Academy of Health Sciences. 2019Dec;6(2):56-9.

Multiloculated thymic cyst: unusual presentation of mediastinal mass

Uttam Laudari¹, Shreya Bhandari², Rupesh Ramtel³, Bibhuti Adhikari³, Mohan Dev Bhandari⁴

¹Lect. Dept. of Surgery, Patan Academy of Health Sciences, Lalitpur, Nepal; ²Dept. of Cardiology, Sahid Gangalal National Heart Centre, Kathmandu; ³Kathmandu Medical College, Kathmandu; ⁴Dept. of Cardiothoracic and Vascular Surgery, Human Organ Transplant Centre, Kathmandu, Nepal

Abstract

Here we present a case of 47 year male found to have large multiloculated thymic cyst during work up done for recurrent pleural effusion. Mediastinal cyst constitutes 10-15% of all radiographically detected mediastinal masses. Thymic cyst account only 5% of mediastinal masses. Thymic cyst can cause difficulty in diagnosis due to its rare presentation, invasive nature and occasional associated with thymic neoplasm. They have been detected incidentally and associated with Sjögren's syndrome, aplastic anemia myasthenia gravis and immunocompromised patients. Here we present a case of 47-year-old male initially work up done for recurrent pleural effusion turned out to be large multiloculated thymic cyst improved after excision which had no associated syndromes and immunocompromised state.

Keywords: mediastinal mass, pleural effusion, thymic cyst

Introductions

Multilocular thymic cysts are rare and few cases are described in the mediastinum.¹ Mediastinal cyst constitutes 10-15% of all radiographically detected mediastinal masses, and thymic cysts account for nearly 5% of all mediastinal masses.² Congenital cysts arise from remnants of thymic duct during the descent of thymic primordial down to the mediastinum and are thin walled with no evidence of inflammation.² Acquired cyst are multilocular with associated inflammatory process, may adhere to surrounding neurovascular structures.^{3,4}

A multiloculated thymic cyst may cause difficulties in diagnosis because of their apparently invasive appearance, varying microscopic features and they may be associated with thymic neoplasms.⁵ We report diagnostic challenge of incidentally found rare large benign multiloculated thymic cyst in a 47-year male who recovered well after surgical excision of the cyst.

Case Report

A 47-year male presented with a history of shortness of breath on exertion, orthopnea, and dry cough in the past few months for which he had received symptomatic treatment. He was a non-smoker and did not consume alcohol. He was a farmer with no significant medical history or contact with

pets. His general condition was unremarkable. There was decreased air entry, dull note on percussion and decreased vocal resonance on right chest with bronchial breath sounds over the right interscapular region. Trachea was shifted to the left. His cardiovascular and abdominal examination were normal.

Hematological, biochemical, serological and tuberculosis workup were normal. Chest X-ray showed homogenous opacity occupying almost the whole of the right lung field and the middle zone of the left lung Figure 1. Ultrasound of the chest was suspicious of a large right mediastinal cyst. However high resolution computed tomography (HRCT) of the chest reported bilateral pleural effusion with a collapse of the right lung, sub-segmental atelectasis in the anterior segment of left upper lobe, small mediastinal and pericardial effusion, Figure 2. It was not clear from the imaging reports whether pathology was pleural effusion or a mediastinal cyst. Echocardiography showed enlarged right ventricle, mild to moderate tricuspid regurgitation

A right-sided video-assisted thoracoscopic surgery (VATS) was performed which revealed a large cystic lesion occupying 3/4th of right chest compressing the right lung with a part of the cyst extending between the aorta and superior vena cava and going into the left chest, Figure 3. To ensure complete excision the incision was converted to a formal right lateral thoracotomy. The cyst contained two

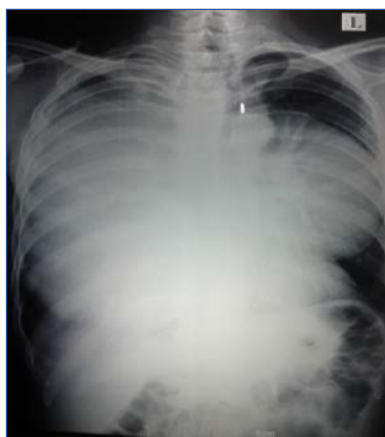

Figure 1. X-ray: Right sided homogenous opacity of lung field

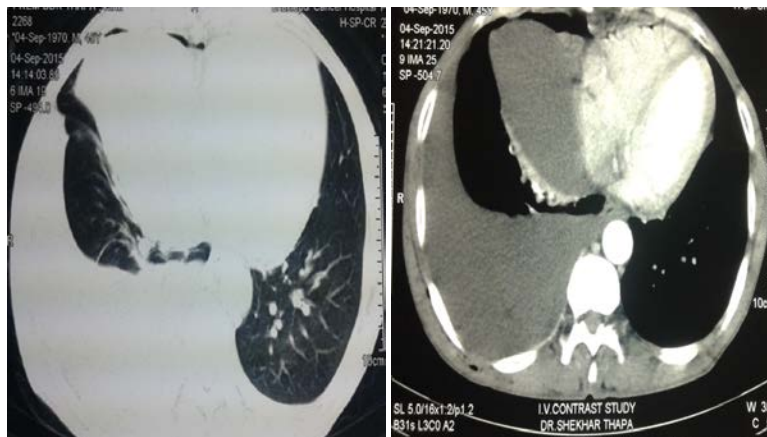

Figure 2. Preoperative CT of the chest showing collapsed lung field and right sided pleural effusion

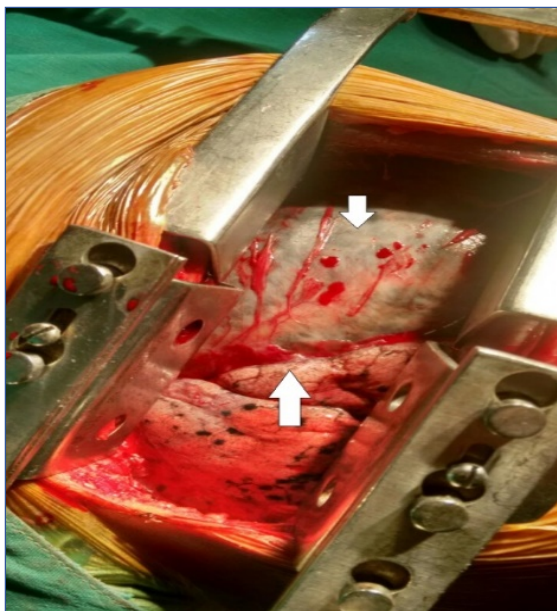


Figure 3. Intraoperative picture showing thymic cyst

litres of thick straw colored fluid, which was sent for analysis. The cyst was completely excised and sent for histology. The postoperative recovery was uneventful and discharged home after drain removal. Postoperative chest X-ray showed satisfactory re-expansion of the right lung, Figure 4. The histopathology showed a multiloculated thymic cyst. In the outpatient clinic a year after the operation, he had good exercise tolerance with no shortness of breath and no evidence of recurrence on chest X-ray.

Discussions

Our case is a 47-year-old patient with right-sided recurrent pleural effusion was found to have a multiloculated benign mediastinal cyst during workup. Ultrasound was suggestive of cystic mass, but CT scan was not able to identify the nature of lesion. True nature of the pathology was confirmed during VATS, which was converted to open thoracotomy with successful surgical excision of the cyst.

A multiloculated thymic cyst may cause difficulties in diagnosis because of invasive appearance, varying microscopic features and associated with thymic neoplasms.⁵ Most cases asymptomatic and diagnosed incidentally on chest x-ray. Some may present

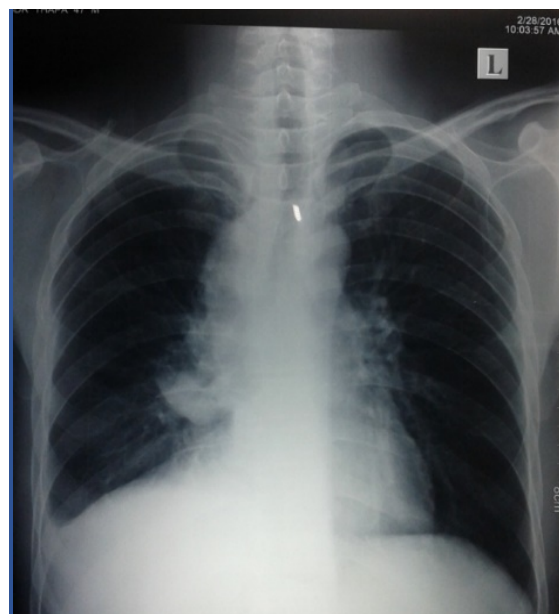


Figure 4. Postoperative X-ray showing expansion of lung (compared to collapsed lung in figure 2)

with chest pain, discomfort and dyspnea.⁵ The cyst may be associated with Sjögren's syndrome, aplastic anemia and myasthenia gravis suggesting an immune-mediated inflammatory process as the cause.³ Unilocular congenital thymic cysts do not recur and are usually cured by a simple cystectomy.⁶

A study in 1995 reported multiloculated thymic cyst in association with Human Immunodeficiency virus (HIV) infection.⁷ Thymic carcinoma has been reported in multiloculated thymic cysts.⁸ Multiloculated cysts often contain turbid fluid and have thick fibrous walls.⁹ Histologically multiple cystic space is lined by squamous or columnar epithelium, and remnants of thymic tissue in the cyst wall with fibrosis and inflammatory changes. Occasionally due to inflammation they may adhere to the adjacent structures and simulate an invasive neoplasm at thoracotomy.¹⁰ On CT chest, the lesion is characteristically demonstrated as mediastinal mass containing multiple cysts along with soft-tissue attenuation.¹⁰

In cases like ours, when radiologic evaluation is inconclusive diagnostic mediastinoscopy, exploratory thoracotomy, video-assisted thoracoscopic surgery, transbronchial or transesophageal aspiration, and CT guided transcutaneous aspiration may be required.¹⁰

Regular followup is necessary as multiloculated thymic cyst may recur postoperatively.⁹

Conclusions

A multiloculated benign thymic cyst in adult male presenting as recurrent pleural effusion was confirmed during video-assisted thoracoscopic surgery, and was converted to thoracotomy for complete excision of cyst. There was no feature of recurrence at one year followup.

References

1. Chaudhari J, Fernandez G, Naik L, Pirosha A. Intrathyroidal multiloculated proliferating thymic cyst. *Endocr Pathol*. 2015;26(1):45-7. DOI PubMed GoogleScholar
2. Prabhakar G, Santhosh AN, Manjunath SS, Santosh KV. Cervical thymic cyst: a case report. *Indian J Otolaryngol Head Neck Surg*. 2013;65(Suppl 1):171-3. DOI PubMed GoogleScholar
3. Choi YW, McAdams HP, Jeon SC, Hong EK, Kim YH, Im JG, Lee SR. Idiopathic multilocular thymic cyst CT features with clinical and histopathologic correlation. *AJR Am Roentgenol*. 2001;177(4):881-5. DOI PubMed GoogleScholar Weblink
4. Jaiswal AA, Garg AK, Ravindranath M, Mohanty MK. Multiloculated cervical thymic cyst: case report with review of literature. *Egypt J Ear, Nose, Throat Allied Sci*. 2014;15(2):129-33. DOI GoogleScholar
5. Suster S, Rosai J. Multilocular thymic cyst: an acquired reactive process: study of 18 cases. *Am J Surg Pathol*. 1991;15(4):388-98. PubMed GoogleScholar Weblink
6. Chetty R, Reddi A. Rhabdomyomatous multilocular thymic cyst. *Am J Clin Pathol*. 2003;119(6):816-21. DOI PubMed GoogleScholar
7. Avila NA, Mueller BU, Carrasquillo JA, Kontny HU, Jaffe ES, Pizzo PA. Multilocular thymic cysts: imaging features in children with human immunodeficiency virus infection. *Radiology*. 1996;201(1):130-4. DOI PubMed GoogleScholar
8. Weissferdt A, Moran CA. Thymic carcinoma associated with multilocular thymic cyst: a clinicopathologic study of 7 cases. *Am J Surg Pathol*. 2011;35(7):1074-9. DOI PubMed GoogleScholar
9. Kondo K, Miyoshi T, Sakiyama S, Shimosato Y, Monden Y. Multilocular thymic cyst associated with Sjögren's syndrome. *Ann Thorac Surg*. 2001;72(4):1367-9. DOI PubMed GoogleScholar
10. Elouazzani H, Zouaidia F, Jahid A, Laraqui L, Bernoussi Z, Mahassini N. Calcified multilocular thymic cyst associated with thymoma: a case report. *J Med Case Rep*. 2011;5(1):225. DOI PubMed GoogleScholar